



SURANA & SURANA NATIONAL TRIAL ADVOCACY
MOOT COURT COMPETITION – 2009

State of TN vs. Santosh & Kenneth
In the Court of Principal Sessions Judge, Chennai

1. Santosh and Murali were friends and studied in the same school. Santosh was brilliant and opted for medical profession. On completion of his MBBS with distinction, he went to the USA to do his masters in surgery specializing in laparoscopic surgeries. Later when laser treatments were in vogue, he enrolled himself for a specialized course in laser surgery using computer aided technologies.
2. Recently he underwent super specialty training on a new concept called lasercut. Lasercut is akin to a surgical knife (a micro thin laser) and is operated using a robotical arm through a computer. The benefit of this method is that benign or malignant tumors however small can be operated accurately. The lasercut arm is a robot with its mechanical arm mounted with a laser beam device that can deliver the accurate dose, and density of the laser beam to the precise location of the diseased area of a patient.
3. On his return to India he joined his father's super specialty nursing home called Cybertreat. He also made immediate arrangements for establishing lasercut technology in his nursing home.
4. Murali meanwhile completed his MBA program and joined his dad's business as a luxury car dealer. Shirin was one year junior to Santosh and Murali in school. She was close to Santosh. Their friendship continued as Shirin also joined medical college with Santosh. She was a good student but not as brilliant as Santosh. She opted for general medicine and ended up as a physician. Shirin was also very friendly with Murali. When Santosh left for higher studies in the USA, Shirin's friendship with Murali intensified and resulted in their Marriage. The marriage was held as a closed family ceremony and many of their common friends did not know this. Santosh was not informed about this.
5. Santosh was shocked to hear about this on his return. He picked up a wordly duel with Murali and Shirin in a hotel bar. His friends pacified him and when he came to senses he apologized profusely to both of them and promised it would never recur and they can be friends again. After a few months everything was normal and the three of them met often and at social gatherings. On April 23 2009 during a dinner party Murali suddenly developed severe pain in his stomach which grew every passing second and at one point he could not control and cried out loud. It was evident that he was in some serious trouble. He was immediately admitted to Cybertreat. The scan report revealed that he had a small tumor in his gall bladder duct leading to the liver touching the duodenum. Santosh opined that there need to be a biopsy done to ascertain malignancy of the tumor. The biopsy revealed that the tumor was benign, but the location caused the problem and could lead to severe conditions if not removed soon.
6. Santosh suggested that he was in the process of installing a robocot that will facilitate accurate treatment with lasercut with a Synchrony system that will significantly improve patient positioning options for treatment. Murali's will be first treatment using the system. Shirin was very apprehensive about this but Santosh talked her into it. He also convinced Murali.

7. The Robocot had a base had 4 holes on four ends that were elongated to fasten it to the floor unit the movement of which is controlled by the computer program that operates the Lasercut. This combined operation is called the Synchrony. This system controls accurate positioning of the Lasercut even if the body is moving due to the breathing of the patient. An electro marker is placed on the diseased part which guides the laser beam. He explained all this to Murali and Shirin and convinced them about accuracy and safety.
8. The day before the surgery, scheduled on May 7 2009, Santosh himself checked all the equipment along with the technical maintenance expert Mr. Kenneth. Shirin was also present for sometime during the inspection. Shirin was wondering why Santosh had to spend so much time on the table (Robocot).
9. Murali and Shirin were informed that there would be five doses of treatment over a period of 1 week. The first two doses were given on consecutive days and the rest three were given on alternate days.
10. On the penultimate day of the treatment, on May 12 2009; Shirin saw Santosh again testing the Robocot late in the evening. On seeing Shirin, he said that he is checking the Synchro.
11. The surgery was completed successfully on May 13 2009. Scan report showed that the tumor has been removed. Murali was in sedation. He was prescribed only liquid diet in small doses and normal diet can be restored in two days time after testing.
12. On the third day, he was given mashed rice with thin soup. Over the evening he developed complication and was writhing in pain. There was an ooze of blood in his nostrils. Immediately he was taken to ICU. A complete scan was taken and a lesion was noticed on the duodenum and in the hepatic duct. Immediately a physical surgery was suggested and carried out. Murali was put in ICU and did not regain consciousness for nearly 36 hours. He woke up on May 19 2009 and saw everybody and enquired what happened to him. While listening he showed constriction of facial muscles and was rocked by sudden seizure. Before medical help could be administered he collapsed. He was pronounced dead. His death certificate revealed that Murali died of cardiac arrest.
13. On May 20 2009 Shirin lodged a complaint with the Thousand Lights police station, that Santosh had planned and murdered Murali avenging for his marriage to her. On the basis of the information given by Mrs. Shirin the police registered the FIR and commenced investigation.
14. An autopsy was performed on May 21 2009. It revealed that there was malignancy at the root of the tumor, which did not show in the biopsy as tissue was taken through laparoscopy on the layer of the tumor.
15. On completion of the investigation, the investigation officer forwarded the final report to the magistrate. The accused were arrested and produced before the magistrate who released them on bail. The magistrate took cognizance of the Report. The case thereafter was committed to the Court of the Principal Sessions Judge, Chennai, who framed charges against the accused. Santosh (A1) was charged in respect of offences punishable under Sections 302 and 120B of the IPC and Kenneth (A2) was charged in respect of offences punishable under Sections 114, 120 and 120B of the IPC. Kenneth was also charged in respect of offences punishable under Sections 65 and 66 of Information Technology Act, 2000 as amended by the IT (Amendment) Act 2008. The case thereafter was posted for trial.

Witnesses

1. Santosh (DW1) (recorded under application from the accused)
2. Kenneth (DW2) (recorded under application from the accused)
3. Shirin (PW1)
4. Expert on lasercut treatment and equipment (DW3)
5. Medical expert (PW2)

Exhibits

1. Laser beam details print & Robocot base fit drawing (Exhibit 1)
2. Diagrammatic detail of diseased part of gall bladder duct (pre and post operative) (Exhibit 2)
3. Scan report (Exhibit 3)
4. Biopsy report (Exhibit 4)
5. Scan Report (Post operative) (Exhibit 5)
6. Scan Report (Exhibit 6)
7. Autopsy report (Exhibit 7)

Documents

1. Case Diary (Summary of Investigation) (Annexure 1)
2. FIR (Annexure 2)
3. Panchnama (Annexure 3)
4. Death Certificate (Annexure 4)
5. Post Mortem Report (Annexure 5)
6. Charge Sheet (Annexure 6)

ANNEXURE 1

Summary of Investigation
(Maintained as per Section 172 Cr.P.C.)
FIR No: 354

P.S. D2, Thousand lights Police Station
Charged under *Sections 120, 302, and 120B IPC 114, & 65 & 66 of IT Act*

Complainant.....State of Tamil Nadu
V
Accused..... Santosh & Kenneth

Investigating Officer: ASI Anil Kumar
Details of Investigation:

May 20, 2009 :

Time of Investigation: 3.00 pm – 4.30 p.m.

On the basis of the information given by Mrs. Shirin, age 27 years, occupation – Doctor, an FIR has been recorded at 1.00 pm on charges under Sections 114, 120, 120 B and 302 IPC and Sections 65 & 66 of the IT Act, 2000 as amended by IT (Amendment) Act 2008

Visited the scene of the occurrence and recorded observations. Photographed the equipment in the operation theatre. Sealed the material evidence in the presence of witnesses, and got the panchnama attested in the presence of witnesses.

Requested for a Medical forensic expert to assist in the on-the-spot investigation.

Requested for Death Certificate

Visited Government General Hospital and requested for Postmortem Report.

Sent the FIR copy to Court through Constable 301 at about 4.40pm.

Ordered for performing Autopsy

May 21, 2009:

Time of Investigation: 9 am – 12 noon, 4 pm – 7.30 pm.

Questioned the accused, named in the FIR.

Recorded a list of witnesses to the ‘occurrence’, along with their details.

Received from Dr. S.P. Mani a copy of the Post Mortem Report, and from Dr. R.P. Kumar, a copy of the Death Certificate.

Autopsy was performed at Govt. General Hospital

May 22, 2009:

Time of Investigation: 10 am – 12.30 pm, 4 pm – 6 pm.

Summoned the witnesses by sending a notice in writing at around 12.00 pm. All witnesses summoned reside within the limits of the police station. The investigating officer reduced the statements given by the witnesses to writing, as per Section 161, Cr. PC.

May 23, 2009

Time of Investigation: 11 am – 12.30 pm, 2.30 pm – 3.30 pm.

On the basis of investigation done, reports made and statements recorded, a final report has been prepared and sent to the Director of Prosecutions, for approval. Obtained approval and filed the Charge Sheet in the Learned Magistrate’s Court at 4 pm.

ANNEXURE 2

FIRST INFORMATION REPORT

(Under Section 154 Cr.P.C.)

1. District: Chennai PS: D2, Anna Salai Year: 2009 FIR No: 354
Date: 20.05.2009

2. Act: I.P.C. Sections 114, 120, 120 B and 302 IPC and Sections 65 & 66 of the IT Act, 2000, as amended by IT (Amendment) Act 2008

3. Occurrence of Offence. Day: 13 May 2009 Date from: 13.05.09 Date to: 19.05.09

Time from: 3.15 a.m. Time to: 4.00 a.m.

b. Information recorded at PS. Date 20.05.09 Time: 12.00 pm Entry No: 1345
Information recorded by: Inspector Gopal

4. Type of Information: Written / Oral : *Written*

5. Place of Occurrence. Direction/Distance from PS : At CyberTreat Hospital – about 1 Km South, from Police Station.

Beat Number :

Address :

In case outside this PS, then the name of PS: District

6. Complainant/Informant, Name : *Mrs. Shirin* Father/husband's name: Late Mr. Murali Vasanth
Date of Birth: *20.04.1982* Nationality *Indian* Passport No: Date of Issue :

Place of Issue:

Occupation: Doctor Address: 17th Cross Street, Saidapet, Chennai 45

7. Basis on which FIR is lodged: *Information given in person, by Mrs. Shirin.*

8. Details of Known/Unknown/Suspected accused with full particulars:
Dr. Santosh (A1) 29 years old; and Kenneth (A2) 30 years old.

9. Reasons for delay in reporting by the complainant/informant:

10. Particulars of Injuries sustained :

- > Surgical cut in the abdomen
- > Nose bleed.

11. Particulars of Post Mortem Report:

Subject – *29-year-old male by name Murali Vasanth, 5'9" height, 80 kg*

Date of death – *19 May 2009*

Time of Death – *between 3.30 & 4.00 p.m.*

12. Post Mortem Report done by: *Dr. S.P. Mani*

13. Inquest report/Unnatural death Case No. if any

ANNEXURE 3

PANCHNAMA

20.05.2009

On 20 May 2009 at 12.00 p.m, the investigating officer, ASI, Anil Kumar visited the spot of the occurrence of the crime in crime number 354 of Thousand Lights Police Station. After observing the place, equipment and the computer room in the area, he prepared a sketch. The operation theatre and the equipment were taken into possession and sealed. Mr. K and L are registration clerks of the operation theatre. They accepted to act as witnesses and have attested the panchnama.

Sd/
ASI Anil Kumar
Investigating Officer

Witnesses:

Signed
Mr. K, age 24 years
Residing at: No. 23, Chellan Street, Thousand Lights, Chennai

Signed
Mr. L, age 31 years
Residing at: No.20, Chellan Street, Thousand Lights, Chennai

ANNEXURE 4

Medical Report/ Death Certificate

20.05.2009

Dr. R.P. Kumar
Regn No: 2468
CyberTreat Hospital
Thousand lights, Chennai

Deceased's Name: Murali Vasanth
Male. Age: 29 years
Height: 5' 9"
Weight: 80 kgs

Date of Death: 19.05.2009
Time of Death: 4.30 a.m
Cause of Death: Cardiac arrest.

Signed
Dr. R.P.Kumar
Duty Doctor

ANNEXURE 5

Post- Mortem Report

21.05.2009

POST MORTEM CONDUCTED BY: Dr. S.P. Mani

Subject: - 29 year old male by name of Murali Vasanth, 5'9" height, 80 kg
Date of Death: 19 May 2009
Time of Death: Between 4.30 a.m. and 4.40 a.m.
Cause of Death: Cardiac arrest due to excessive internal hemorrhage

Injuries on the person of the deceased: -

1. A surgical cut in the abdomen leading liver and gall bladder
2. Nose bleed.

Signed
Dr. S.P. Mani

ANNEXURE 6

Charge Sheet:
(u/s 173 Cr.P.C.)

In the Court of the I Class Judicial Magistrate, Saidapet

Final Report in Cr No 300/2009

Complainant

State of Tamil Nadu

Vs.

Accused

1. Dr. Santosh, age 29, s/o Dr. Amardeep, residing at No: 12, Gandhi Nagar, Chennai 6
2. Mr. Kenneth S/o, Mr. Thomas, age 31 years, residing at No 16, Pudupet, Chennai 2
U/s 302, & 120B and for Kenneth under section under 114, 120, 120B and of the IPC and under Section sec. 65 & 66 of the IT Act 2000 as amended by IT (Amendment) Act 2008

Summary of Facts:

Dr. Santosh and Mr. Murali Vasanth, a businessman were school friends. Murali married Dr. Shirin who was an year junior in school and studied medicine in the same medical college where Santosh also studied. Dr. Santosh and Shirin were very close and it was rumored that they would marry. But when Dr. Santosh went abroad (USA) for higher studies, Shirin developed intimacy with Murali and married him. After Santosh returned from abroad, there was an incident at a restaurant when Santosh picked up a quarrel with Murali over Shirin and there was an altercation. Later they made up and vowed never to quarrel.

On April 23 2009 at a dinner party, Murali developed severe stomach pain which Dr. Santosh attended and advised complete check up. After thorough checkup Santosh suggested laser surgery with the latest equipment called Lasercut installed in his ultra modern nursing home CyberTreat.

Dr. Santosh himself took great interest in the surgery and personally checked the instruments himself before the surgery. Shirin complains that he spent lot of time in directing the fixing of the surgical table and the equipment which is controlled by a computer. The computer and the equipment was operated by a Technician Mr. Kenneth. The treatment was given for 3 days continuously and later on alternate days for two days.

Previous day to the surgery i.e. 12 May 2009, it is reported that Dr. Santosh checked the equipment again. The surgery was completed successfully on 13 May 2009. After three days when normal food was resumed for the patient, complications developed and patient lost consciousness for nearly 36 hours. On 19 May 2009 morning, patient woke up and enquired what happened to him, but immediately he developed fits and was rocking violently and collapsed. He was pronounced dead due to cardiac arrest.

PW 1 then went to the D2 Police Station, Anna Salai, where Inspector Gopal, recorded the FIR., at 12.,00 pm, for offences under Sections 114, 120, 302, and 120B and Sections 65 and 66 of Information Technology Act, 2000.as amended by IT (Amendment) Act 2008

A1 Mr. Santosh is liable to punished under Sections 302 and 120B of the Indian Penal Code, 1860 and A2 Mr. Kenneth is liable to be punished under Sections 114, 120 and 120B of IPC and Sections 65 and 66 of Information Technology Act, 2000.as amended by IT (Amendment) Act 2008

ASI Anil Kumar, Investigating Officer, D2 Police Station, Anna Salai.

STATEMENT OF WITNESSES

Persons examined:

1. Mrs. Shirin
2. Dr. Anderson, Medical Expert
3. Dr. S. P. Mani – Postmortem Report
4. Mahazar Witness (sealing of operation theater with equipment and computers)
5. Mahazar Witness (sealing of operation theater with equipment and computers)
6. ASI, Anil Kumar, Investigating officer

1. Mrs. Shirin

I am wife of the deceased Mr. Murali Vasanth. I am a doctor by profession. Murali and Santosh and I studied in the same school. I was a year junior to them. We were all good friends. I married Murali. Santosh was in the US for higher studies at that time. On his return from US Santosh set up his hospital. In a party. I had no intention of marrying Santosh. I don't understand why he bitterly quarreled with Murali for marrying me. When Murali fell ill, Santosh was at hand to give immediate treatment. I wanted to take him to a different hospital. But Santosh insisted that I try Cyber treatment. I now regret the decision.

2. Dr. Anderson (Medical expert)

I have seen the scan, the biopsy and autopsy reports of the deceased. Generally surgery in the gallbladder or tumors surrounding the gall bladder area, duct etc. is not very complicated and is not fatal. I also see that during the autopsy, the under portion of the tumor was diagnosed malignant. The laceration on the duodenum is surprising considering the accuracy of Lasercut. I am familiar about such treatment being given in hospitals abroad. They are fairly safe.

3. Dr. S. P. Mani – Postmortem Report

The postmortem on the dead body of the deceased was conducted by myself. The following injuries were present on the person of the deceased:-

Subject – 28 year old male by name Murali Vasanth, 5'9" height, 80 kgs

Date of death – 19.05.2009

Time of death – 4.00 p.m.

- 1 A surgical cut in the abdomen leading to liver and gall bladder
- 2 Nose bleed

I endorsed on the post-mortem report that the surgical cut was made for the purpose of carrying out a Lasercut treatment for placing the electronic marker. The cause of death was ascertained as cardiac arrest due to excessive internal hemorrhage and multiple organ failure.

4. Mahazar Witness (sealing of operation theater and equipment)

On 20.05.2009 the police inspector requested me to check the list of things he prepared that were in the operation room and computer room. I checked and they were matching. Thereafter he sealed the room with the contents.

5. Mahazar Witness (sealing of operation theater and equipment)

On 20.05.2009 the police inspector requested me to check the list of things he prepared that were in the operation room and computer room. I checked and they were matching. Thereafter he sealed the room with the contents.]

6. Investigating officer

I, Anil Kumar am the ASI in Thousand lights, and the investigating officer in this case. On 1 June 2009, after ascertaining the facts from the various people investigated, have taken A1 & A2 into custody and charged Santosh under Sections 120, 302, & 120B of IPC & Kenneth under section under 114, and 120B of the IPC and under Section sec. 65 & 66 of the Information Technology Act, 2000.as amended by IT (Amendment) Act 2008

Exhibit 1 - Lasercut equipment picture and illustration of base mechanism

Picture 1

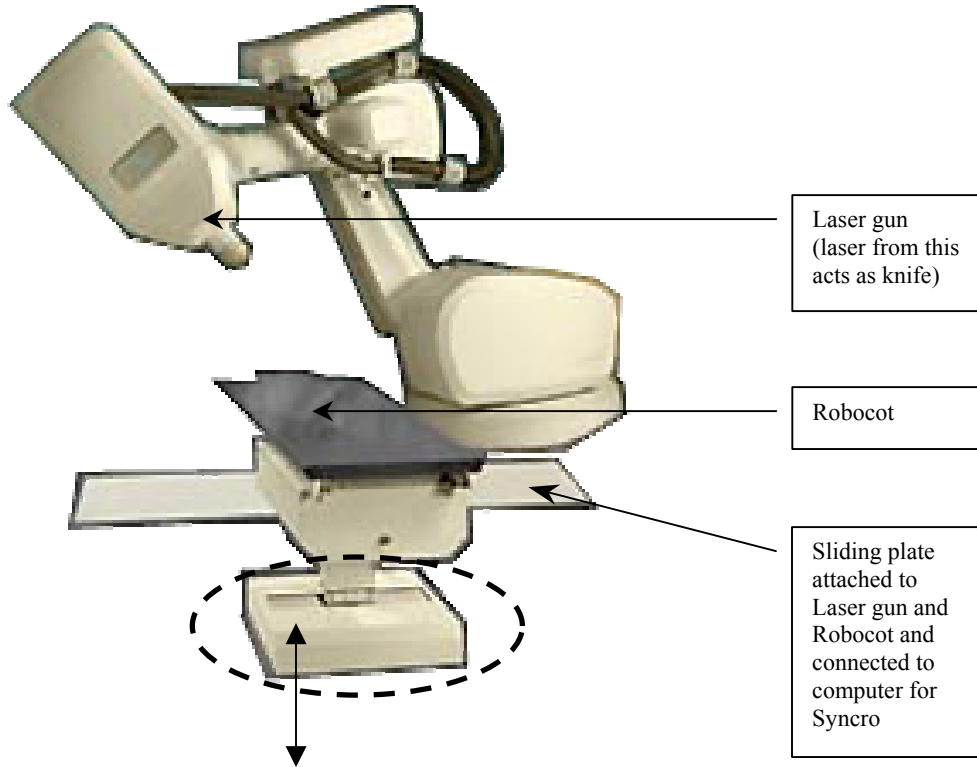


Illustration of top view of the base
(Shown circled in picture of Lasercut above)

Picture 2

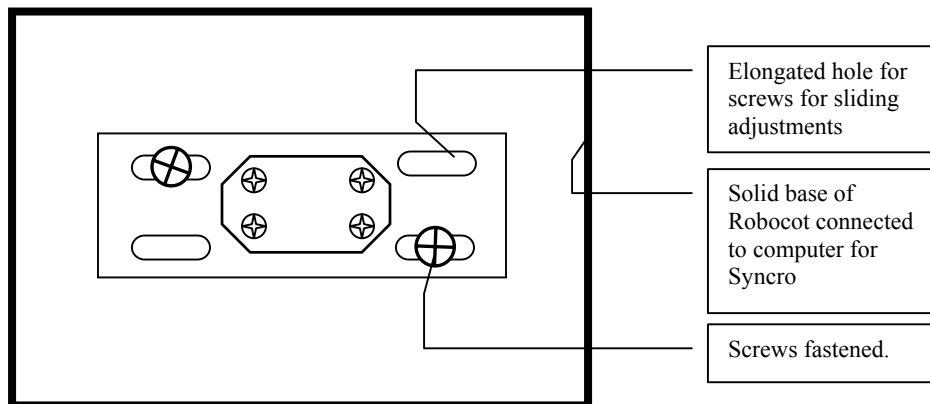
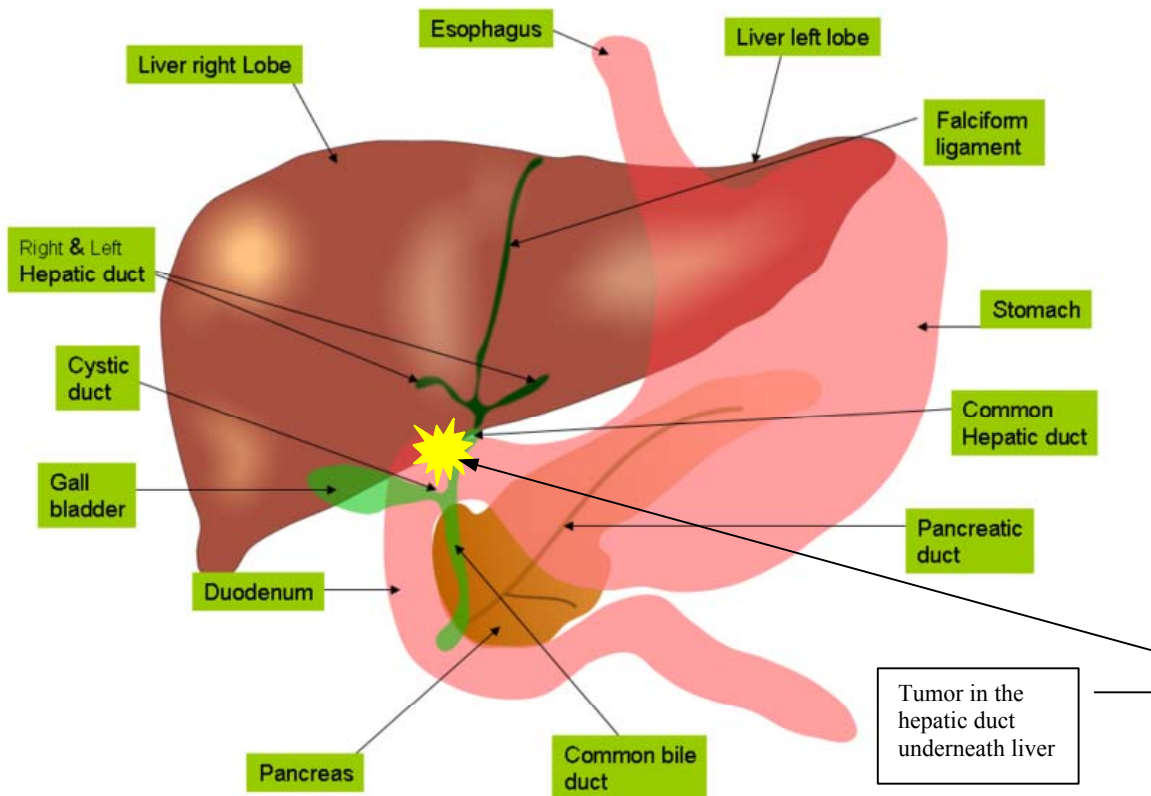


Exhibit 2 - Diagrammatic detail of diseased part of gall bladder duct

Pic



http://en.wikipedia.org/wiki/File:Anatomy_of_liver_and_gall_bladder.png

Picture 2 – After surgery

(Image that showed in autopsy report)

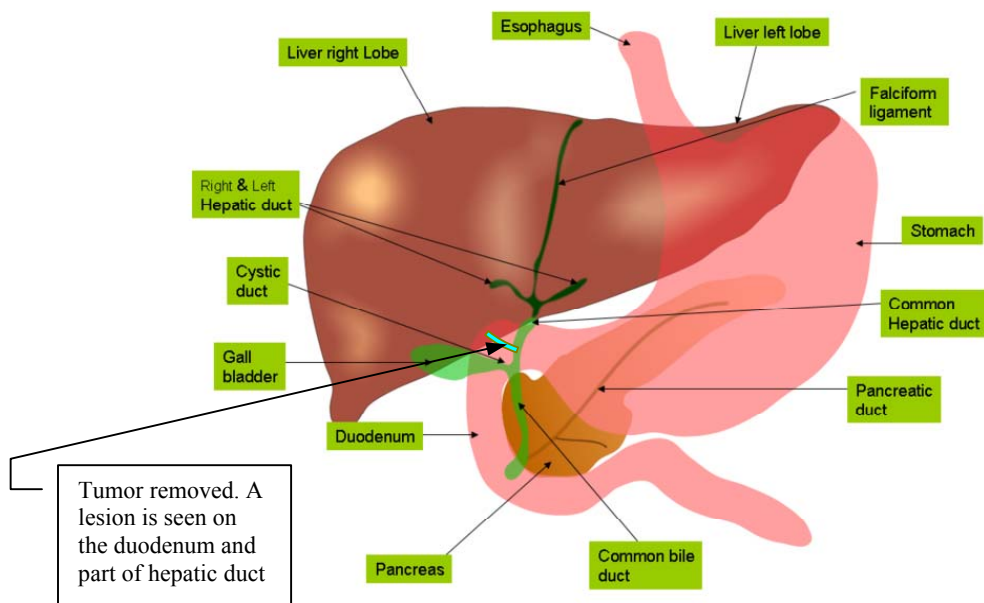


Exhibit 3

CT Scan Report: April 23, 2009

Report from Vazhkai Hospital
65 Ganesh Salai, Chennai
Diagnostic Imaging Report
Exam Date: April 23, 2009
Scan #: 04-2727

CT ABDOMEN and PELVIS (Dynamic)

Axial 10 mm cuts were obtained from the diaphragm down to the symphysis pubis. Additional 10-mm cuts were also obtained through the liver during the dynamic intravenous administration of 100 cc Optiray 320.

A growth on the gallbladder duct is observed. The cell mass appears on the gallbladder duct at its connection point with the duodenum.

A biopsy of the growth tissue is recommended.

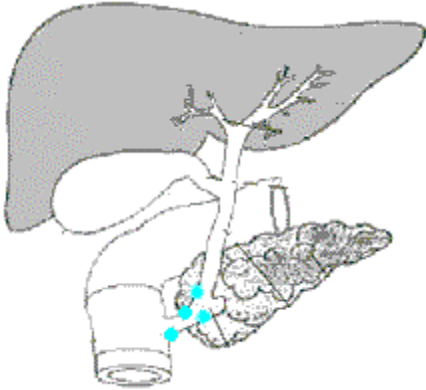
Dr. Dipesh Mehra (radiologist)

cc. Dr. Santosh
cc: Dr. Julia Thomas

Exhibit 4

Pathology Report

Cybertreat Nursing Home



Patient Name (Last, first): Murali, Vasanth.	
Date of biopsy	April 29, 2009
Number of cores obtained *	4

*Check here if each core placed in separate container

Legend

● = No malignancy ● = Malignancy

SPECIMEN DETAILS

Site (cross-section)	Length (mm)	Malignancy (Yes/ No)	Malignant area size (mm) (%)
1 left base	10	N	-
2 left mid	7	N	-
3 left apex	5	N	-
4 right base	5	N	-
Totals	27 mm	0/4	0

Description:

Tumor cells do not show malignancy _____

Julia Thomas, M.D.

Exhibit 5

CT Scan Report: May 14, 2009

Cybertreat Nursing Home
65 Ganesh Salai, Chennai
Diagnostic Imaging Report
Exam Date: May 14, 2009
X-Ray #: 11-5206

Patient: Mr. Murali Vasanth

CT ABDOMEN and PELVIS (Dynamic)

Axial 10 mm cuts were obtained from the diaphragm down to the symphysis pubis during the dynamic intravenous administration of 100 cc Optiray 320.

The cell mass detected in Scan #04-2727 (April 24, 2009) is absent. Surgical intervention appears to be successful.

Dr. Dipesh Mehra (radiologist)

cc. Dr. M.C. Santosh
cc: Dr. Julia Thomas

Exhibit 6

CT Scan Report: May 19, 2009

Cybertreat Nursing Home
65 Ganesh Salai, Chennai
Diagnostic Imaging Report
Exam Date: May 19, 2009
X-Ray #: 11-5206

Patient: Mr. Murali Vasanth

CT ABDOMEN and PELVIS (Dynamic)

Axial 10 mm cuts were obtained from the diaphragm down to the symphysis pubis during the dynamic intravenous administration of 100 cc Optiray 320.

A small lesion in the duodenum extending to the hepatic duct is noticed.

Dr. Dipesh Mehra (radiologist)

cc. Dr. M.C. Santosh
cc: Dr. Julia Thomas

22 May 2009

Autopsy done by Dr. Abhilasha Sharma

DECEDENT: Murali Vasanth

EXTERNAL EXAMINATION

The deceased is a well developed, well nourished male. The body weighs 85 kg, is 180 cm in height and appears compatible with the stated age of 29 years.

INTERNAL EXAMINATION

The thoracic and abdominal organs are in their normal anatomic positions.

Cardiovascular system. The heart is large with a normal shape and weighs 397 grams. The pericardium is intact. The left main coronary artery shows evidence of dilatation and thrombosis. The gross cut section shows an acute myocardial infarction. The left ventricles are not dilated and not hypertrophied. Left anteroseptal wall is dark red. The valves are unremarkable.

Respiratory System. The larynx is unremarkable. The epiglottis is freely movable. The lungs weigh 1,340 grams together. The pleural surfaces are smooth and glistening. On cut surface, the pulmonary parenchyma is red-purple, congested, exuding a slight amount of blood and frothy fluid. The bronchi are of normal caliber and color.

Gastrointestinal System. The esophagus is smooth and tan. The stomach is thin, without rugae or ulceration. The small and large intestines are unremarkable. The liver weighs 3000 grams and lies within the costal margin. The gallbladder contains tumor cells with extreme pleomorphic changes growing diffusely on the duct and contains yellow-green-brown, mucoid bile. The extrahepatic biliary tree is patent, without evidence of calculi. The pancreas has a normal gray-white lobulated appearance; pancreatic ducts are patent and unremarkable.

Endocrine System. The thyroid weighs 12.4 grams and is unremarkable. The right and left adrenal gland weigh 8.0 and 11.6 grams, respectively, and they are unremarkable.

Musculoskeletal System. No significant pathology was grossly found.